

Myocarditis and vascular injury as a result of COVID-19

Case reports overview

Content

- Introduction
- SARS- CoV-2 and myocarditis
- SARS-CoV-2 and vascular injury
- Lessons from the SARS-CoV-2 infection
- Discussion

Introduction

SARS-CoV-2 ...

- December, 2019, Hubei ¹....

- ... Pandemic:

7 941 791 confirmed cases

434 796 deaths ²

- Clinical manifestations: respiratory, cardiovascular,...

SARS-CoV-2 and myocarditis³

First reported case: Shenzhen, China

The patient

63-year old, male

- White sputum expectoration
- Fever 39.3 °C
- Dyspnea
- Chest tightness

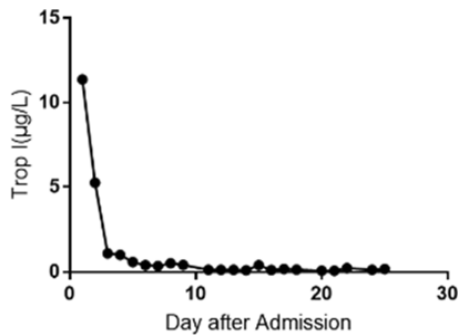
Sputum testing
SARS-CoV-2

Laboratory findings:

- pH= 7.049
- $\text{PCO}_2=76.4$ mmHg,
- $\text{PO}_2 = 66.2$ mmHg,
- $\text{SaO}_2= 91.8\%$
- ALT=97 U/L
- Cr= 157 $\mu\text{mol/L}$
- hematuria

Myocardial injury markers

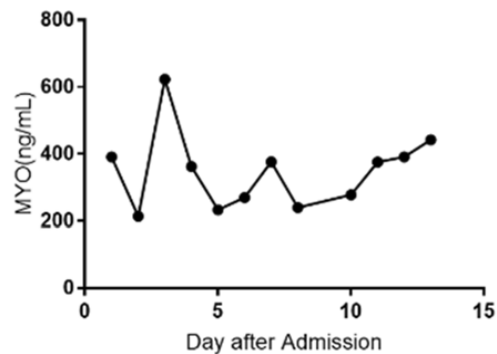
Trop I=11.37
g/L



A

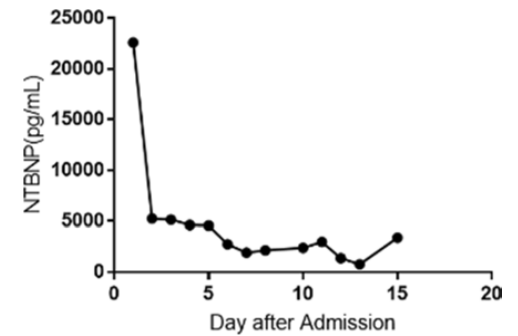
0.10 g/L

Myo=390.97
ng/mL



B

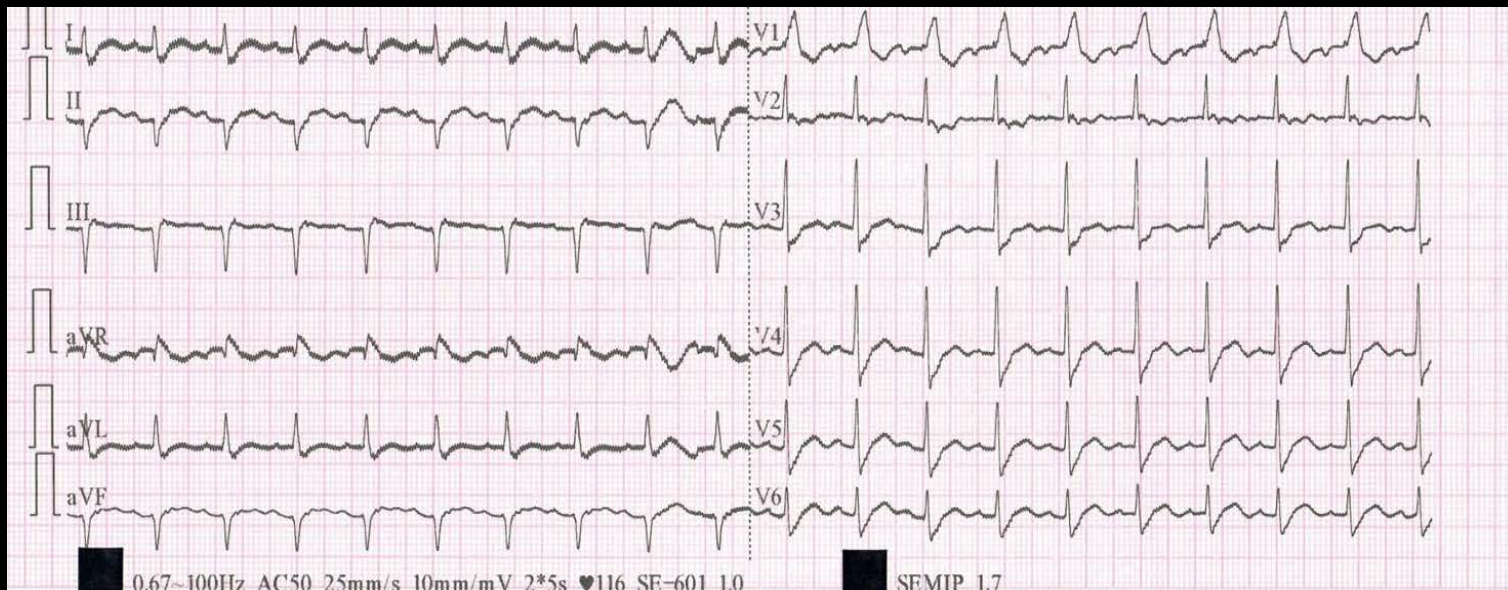
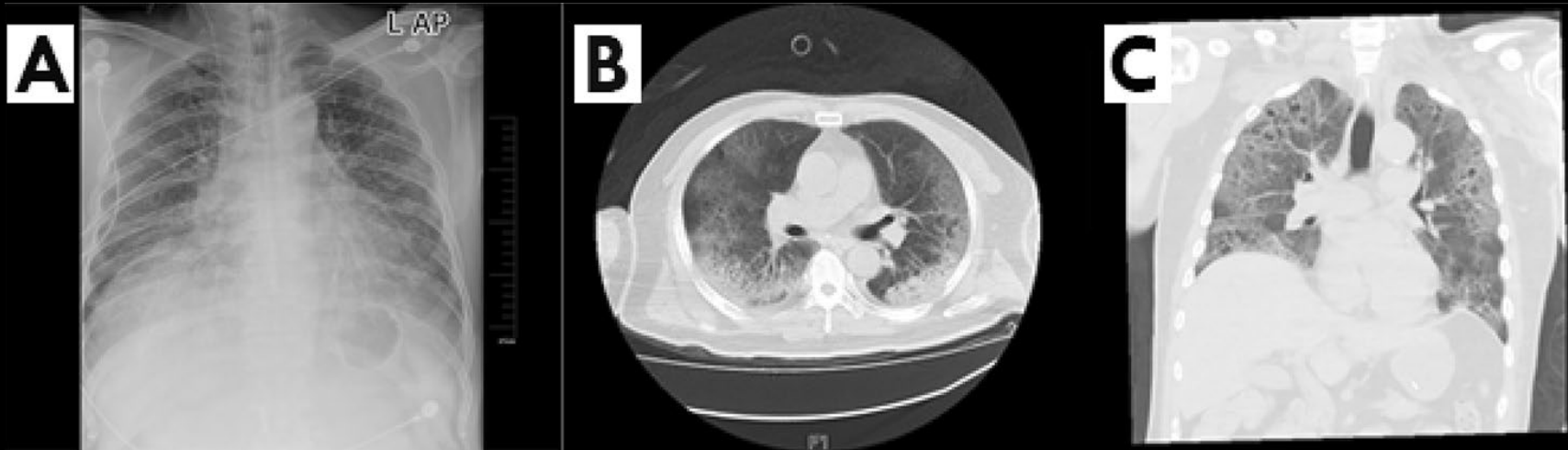
NTBNP= 22,600 pg/mL



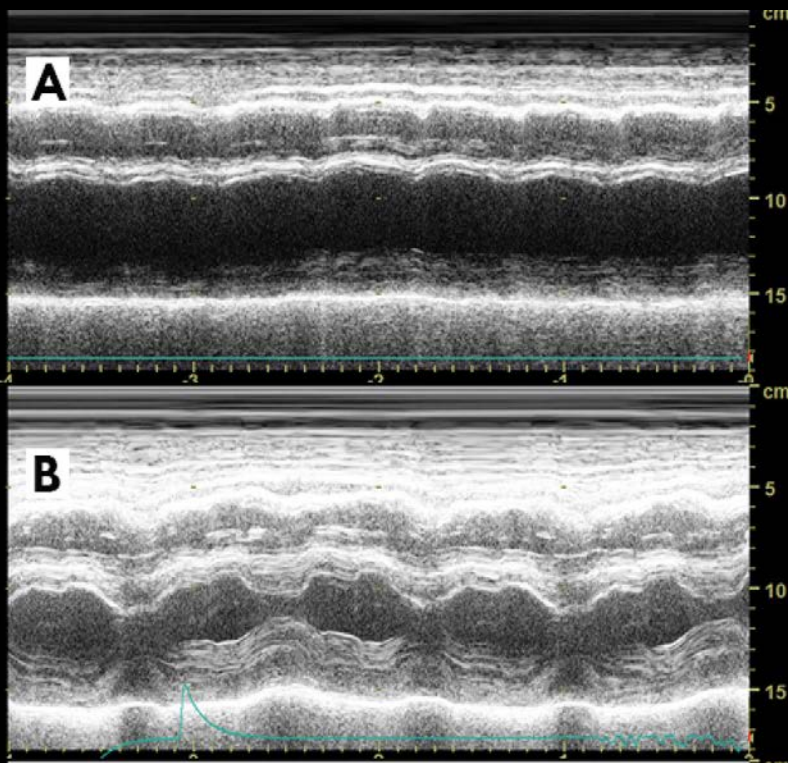
C

750 pg/mL

Paraclinical investigations



Echocardiography



- LV= 61 mm
- Dyskinezia
- LVEF= 32%
- PASP= 44 mmHg

Diagnosis, treatment

- Severe pneumonia, fulminant myocarditis, MODS
- ventilatory support,
- lopinavir-ritonavir,
- methylprednisolone,
- immunoglobulin,
- piperacillin-tazobactam,
- continuous renal replacement therapy

Clinical course

- Lung lesions progression
- Ventricular septum= 14 mm
- IL-6= 272.40 pg/mL
- ECMO

- IL-6= 7.63 pg/mL

- infection-related markers increased ... septic shock, DIC

SARS-CoV-2 and myocarditis

- sudden onset,
 - symptoms of viral infection,
 - severe myocardial injury,
 - diffuse decreased ventricular wall movement.
-
- likely to be caused by SARS-COV-2
-
- elevated IL-6 (cytokine storm?)

SARS-CoV-2 and vascular injury⁴

Report of five cases

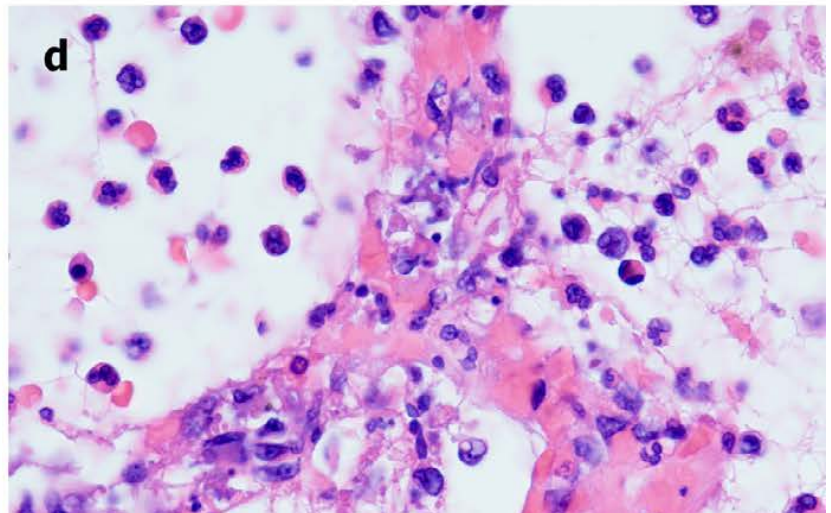
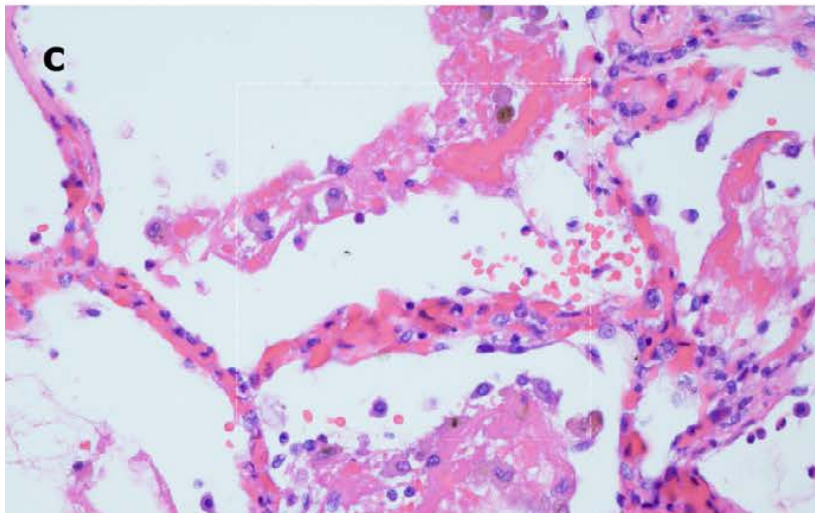
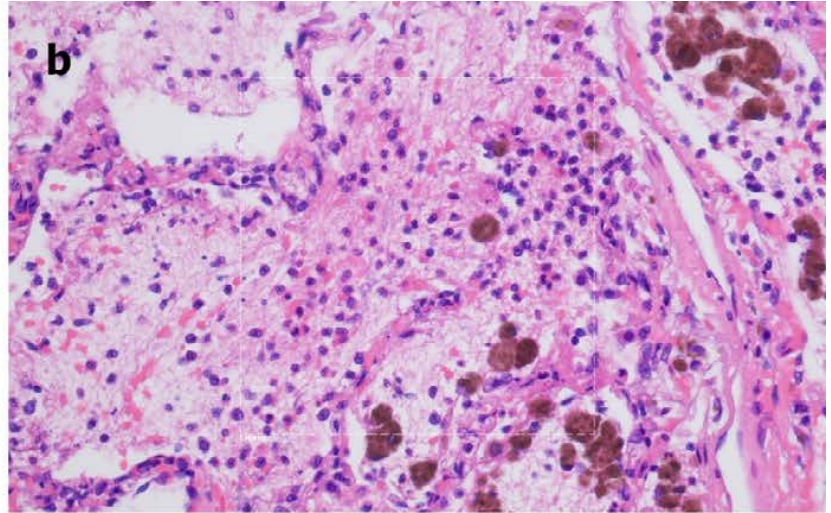
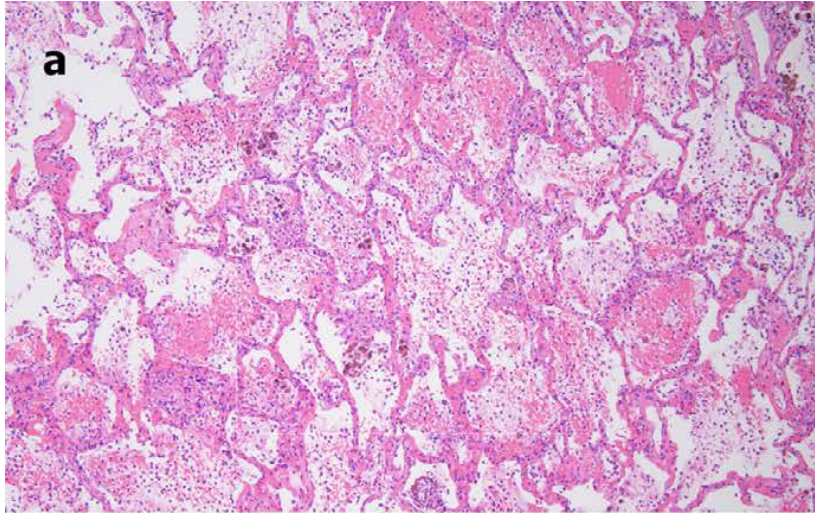
Report

- 5 patients with SARS-CoV-2 infection and severe respiratory failure,
- 3 of whom also had features of a systemic procoagulant state

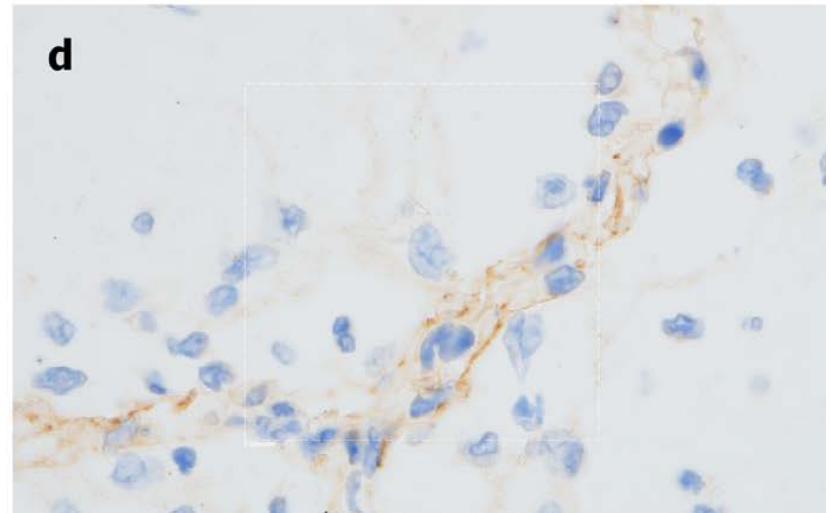
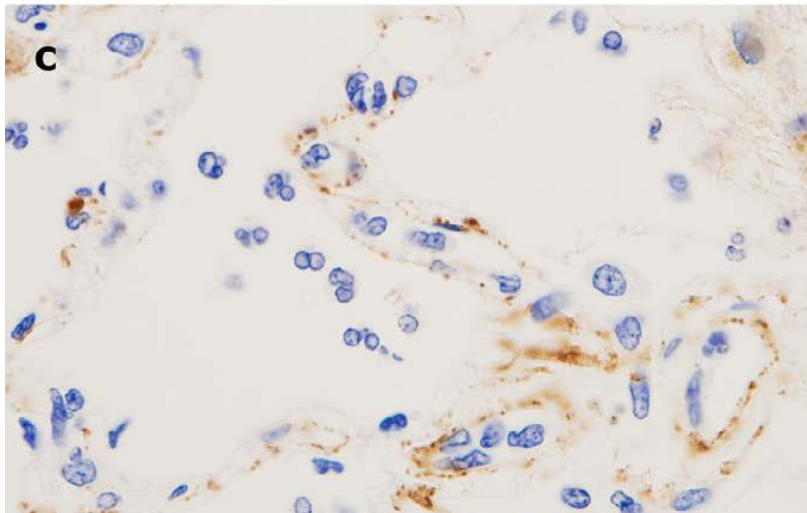
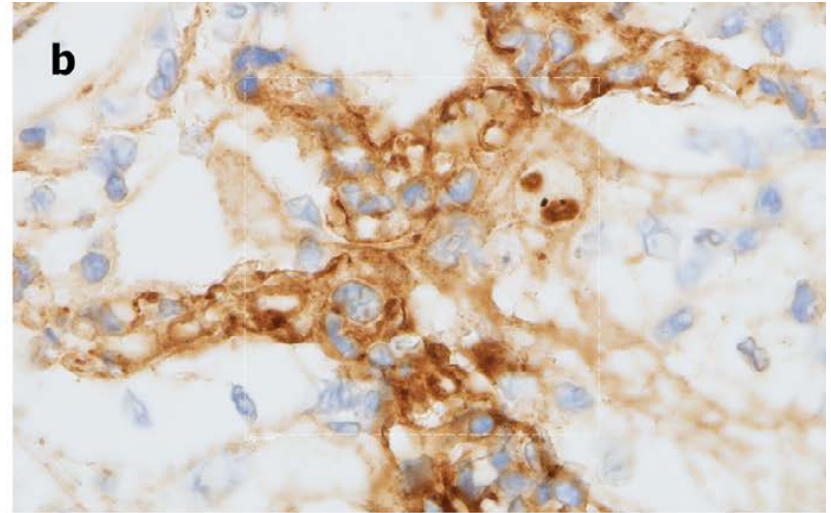
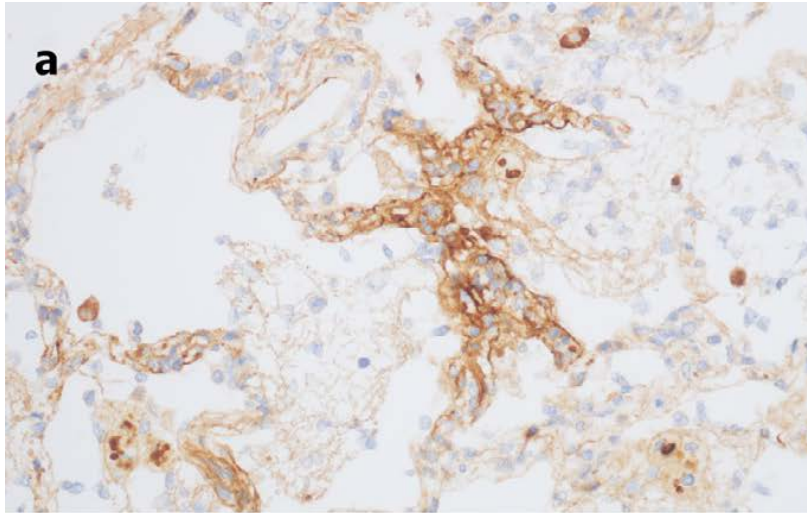
- Lung and cutaneous tissues

- Histologic and immunohistochemistry studies

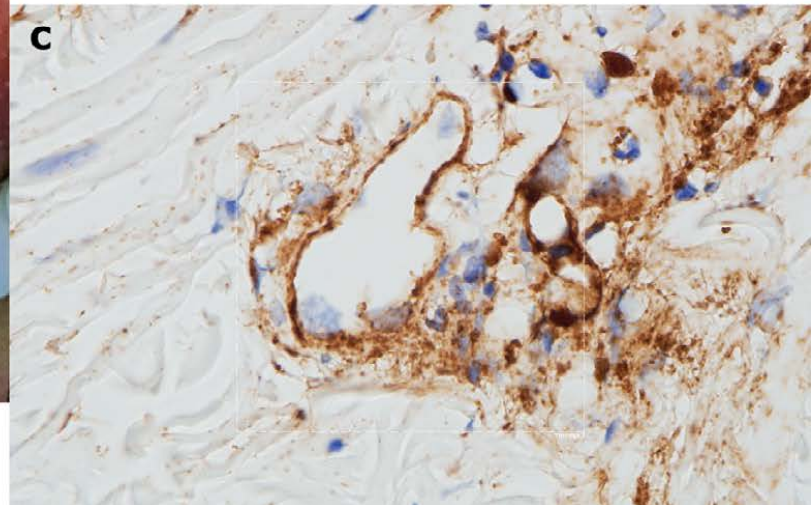
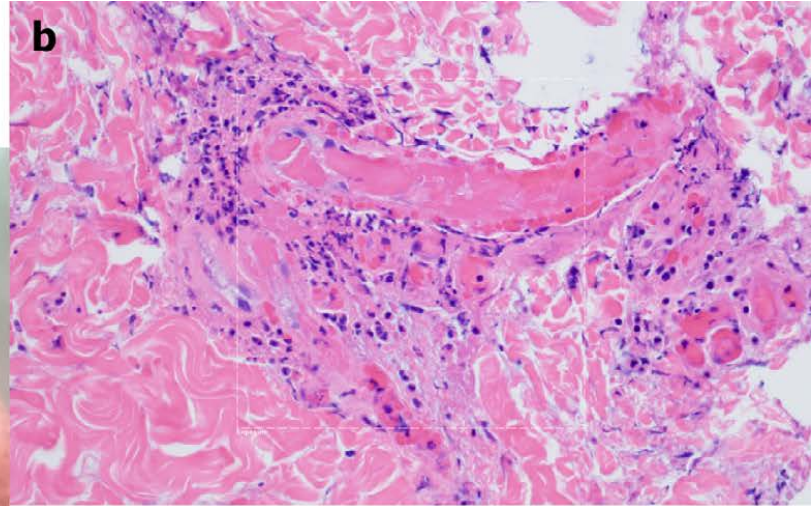
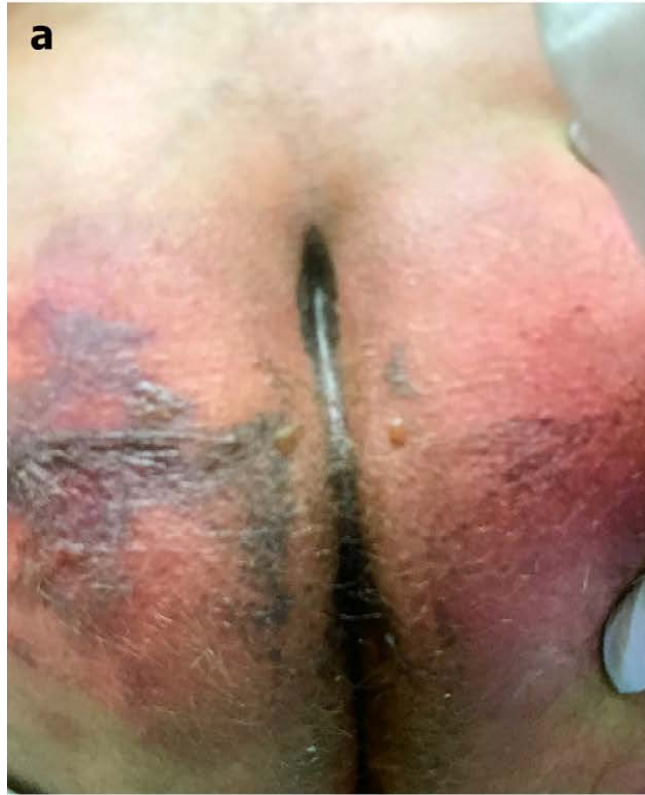Histologic study of lungs



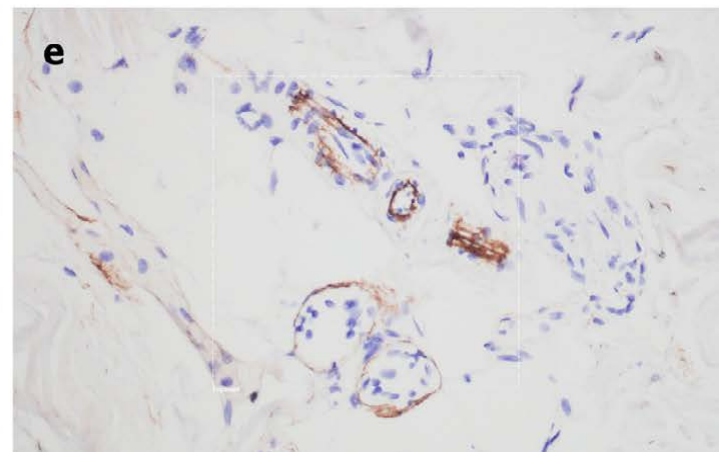
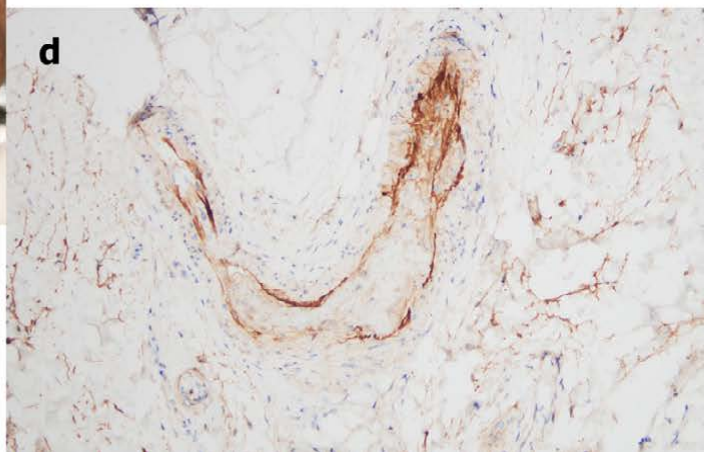
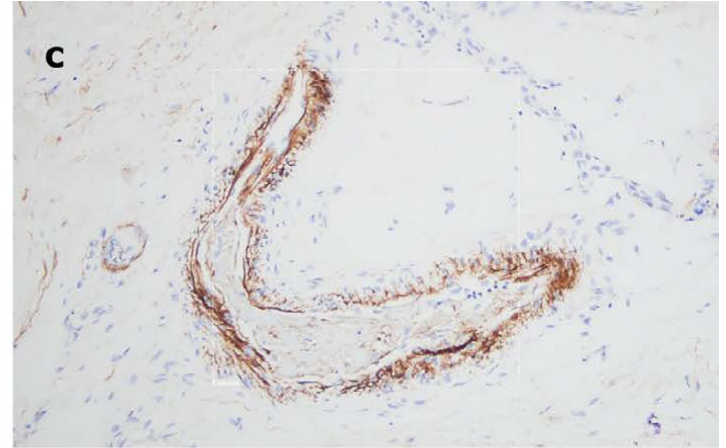
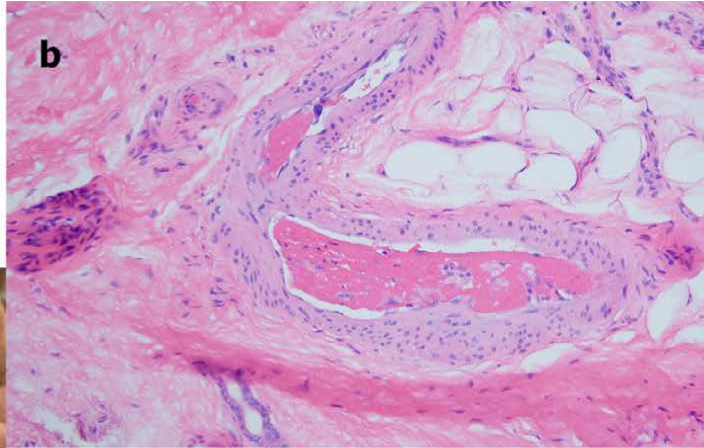
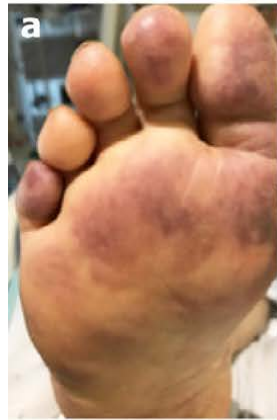Immunohistochemistry analysis of lungs



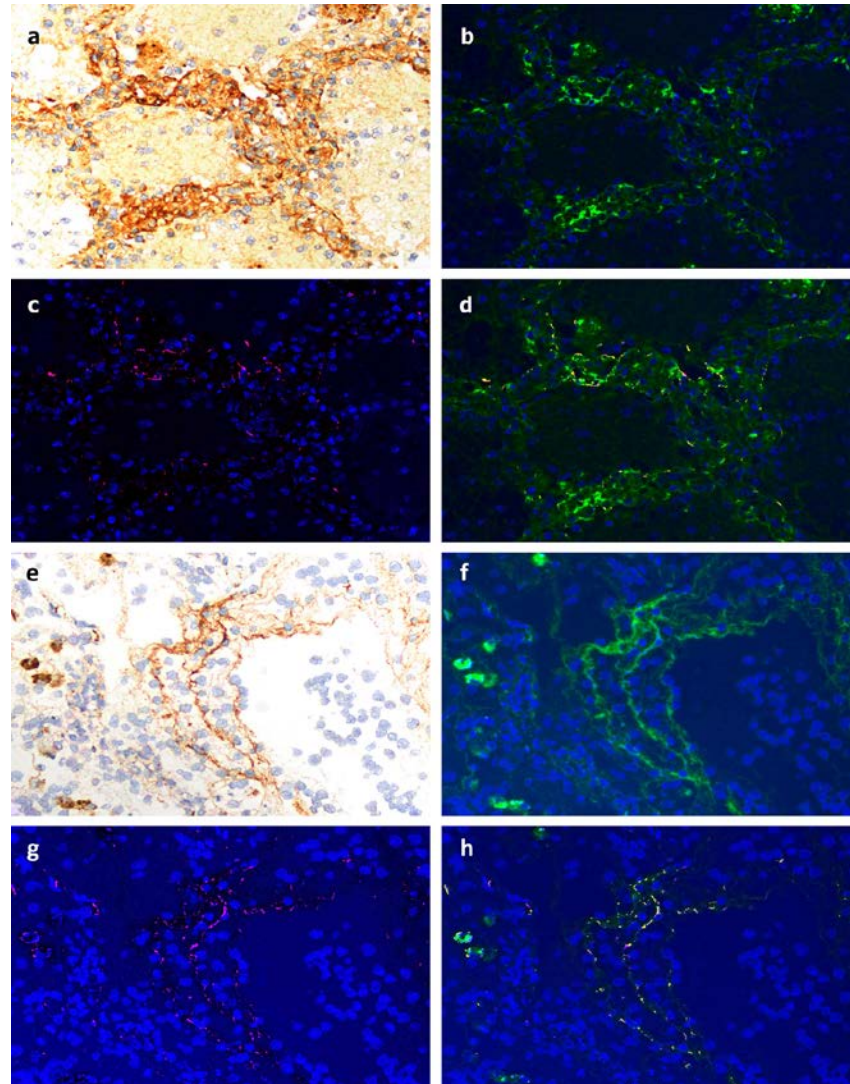
Retiform purpura



Livedo racemosa



Immunofluorescence - NUANCE



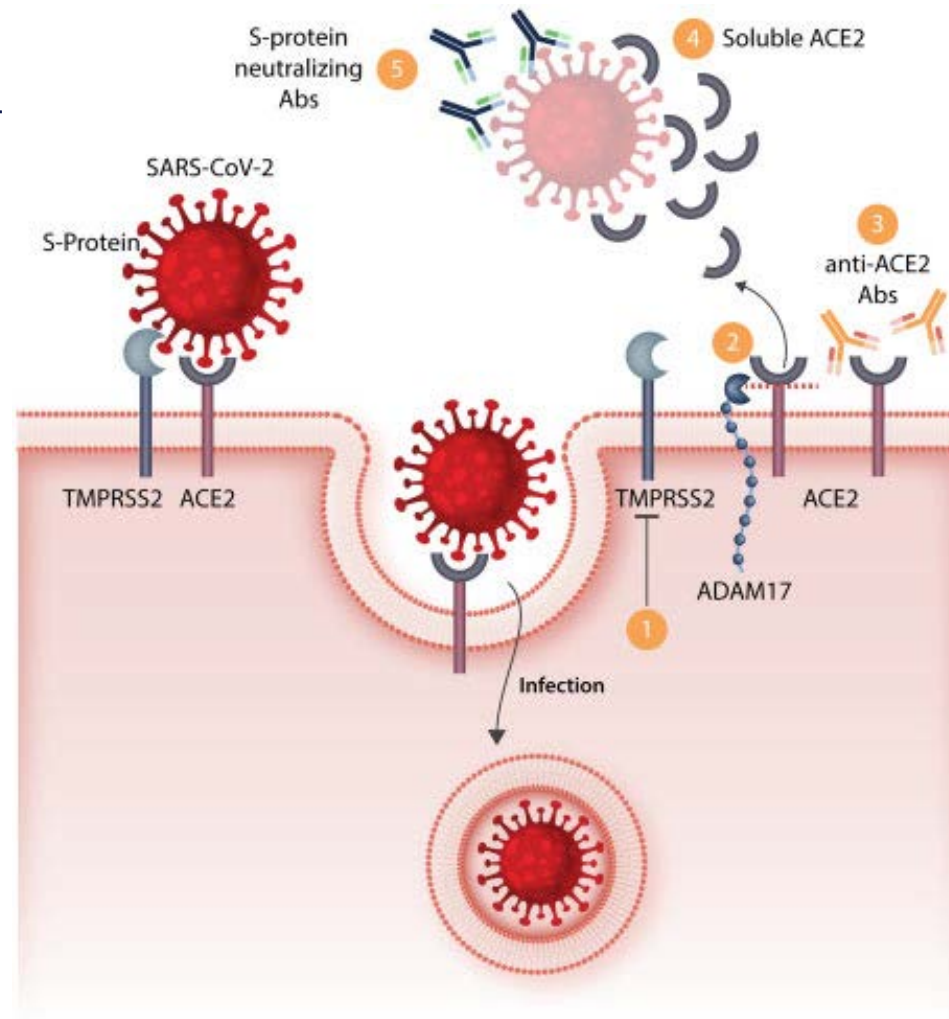
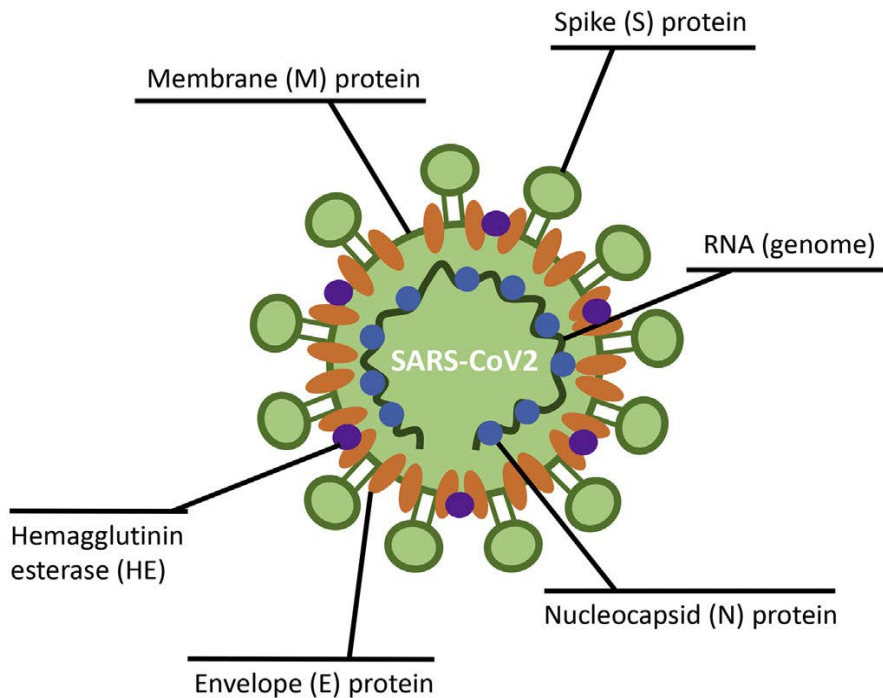
SARS-CoV-2 and vascular injury

- Generalized thrombotic microvascular injury
- Complement activation
- C5b-9, C4d deposits in lungs, skin
- alveolar capillaries

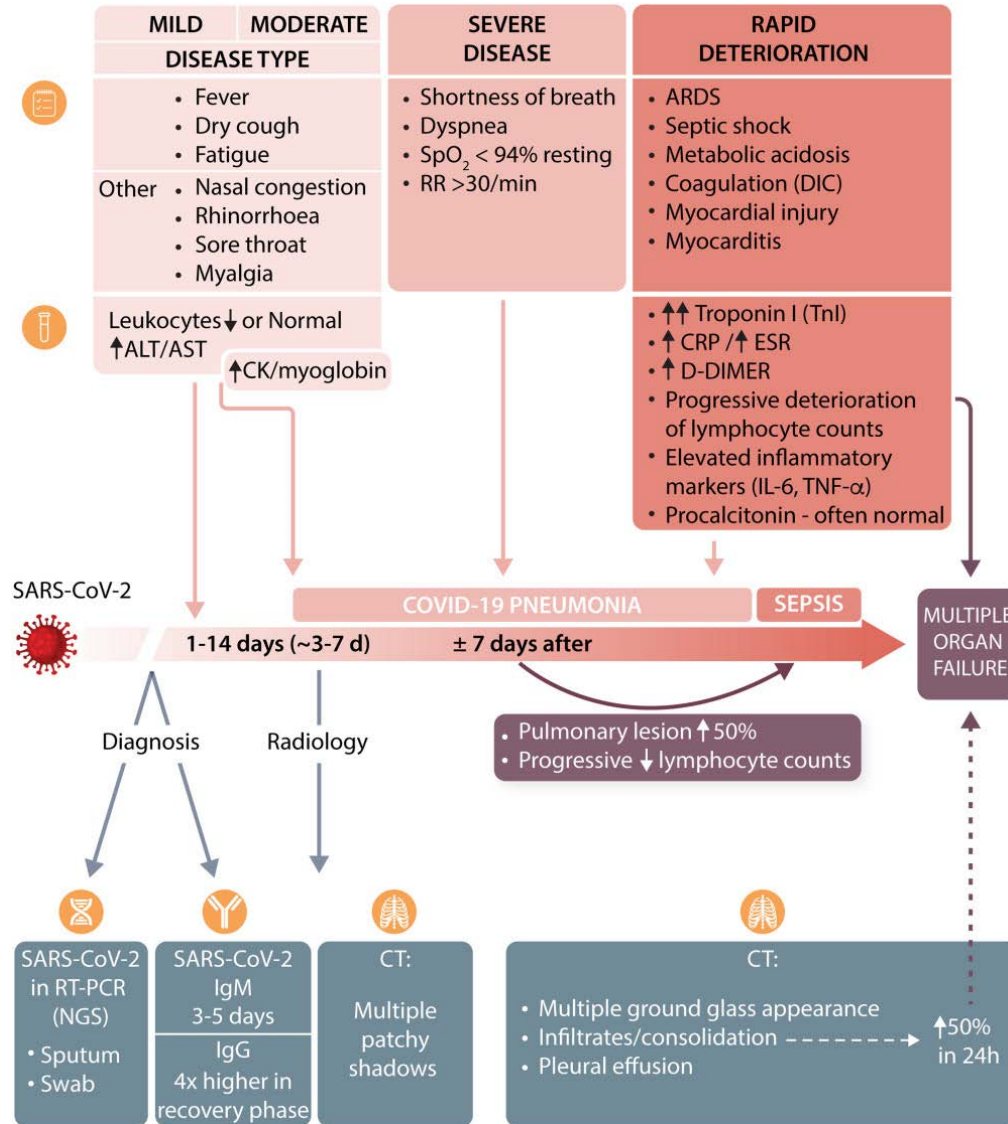
Lessons from the SARS-CoV-2 infection^{5,6}

Viral structure

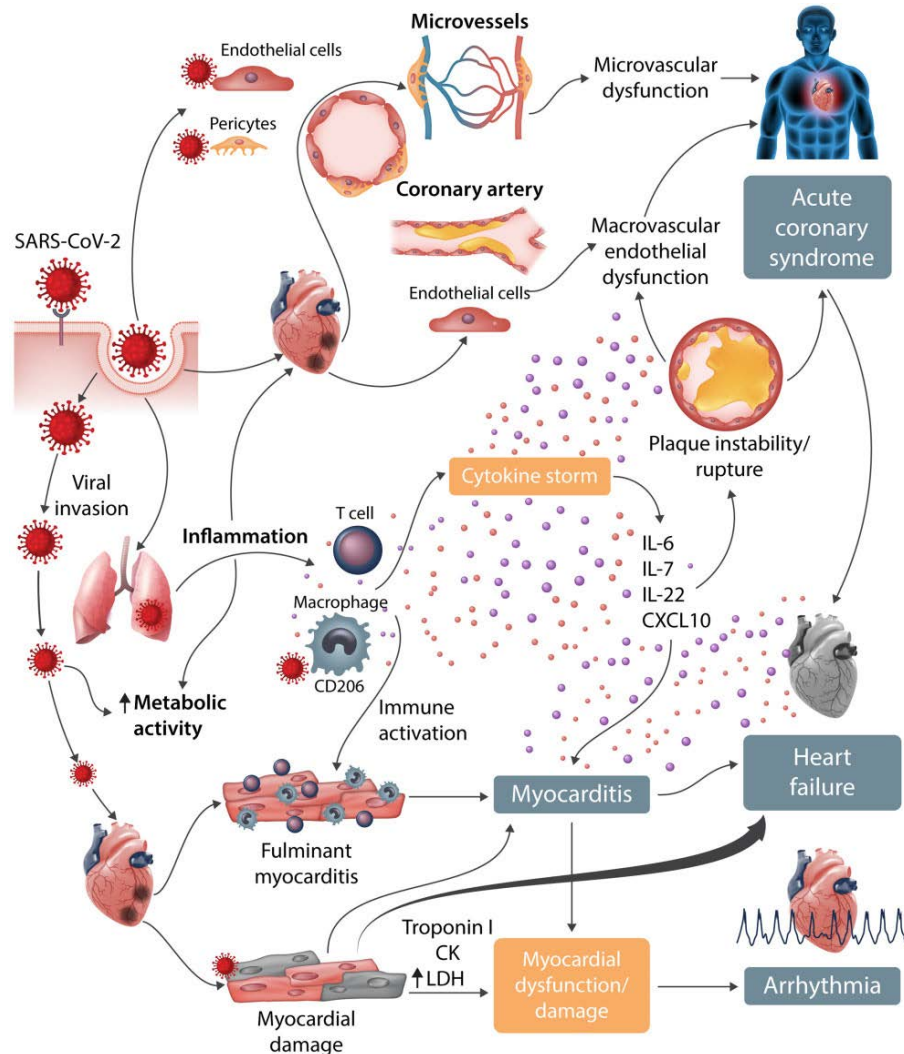
Cell entry mechanism



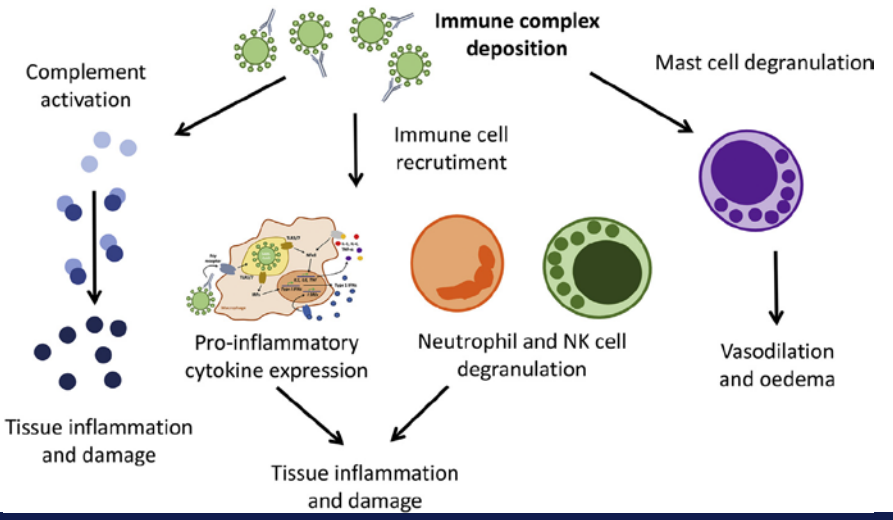
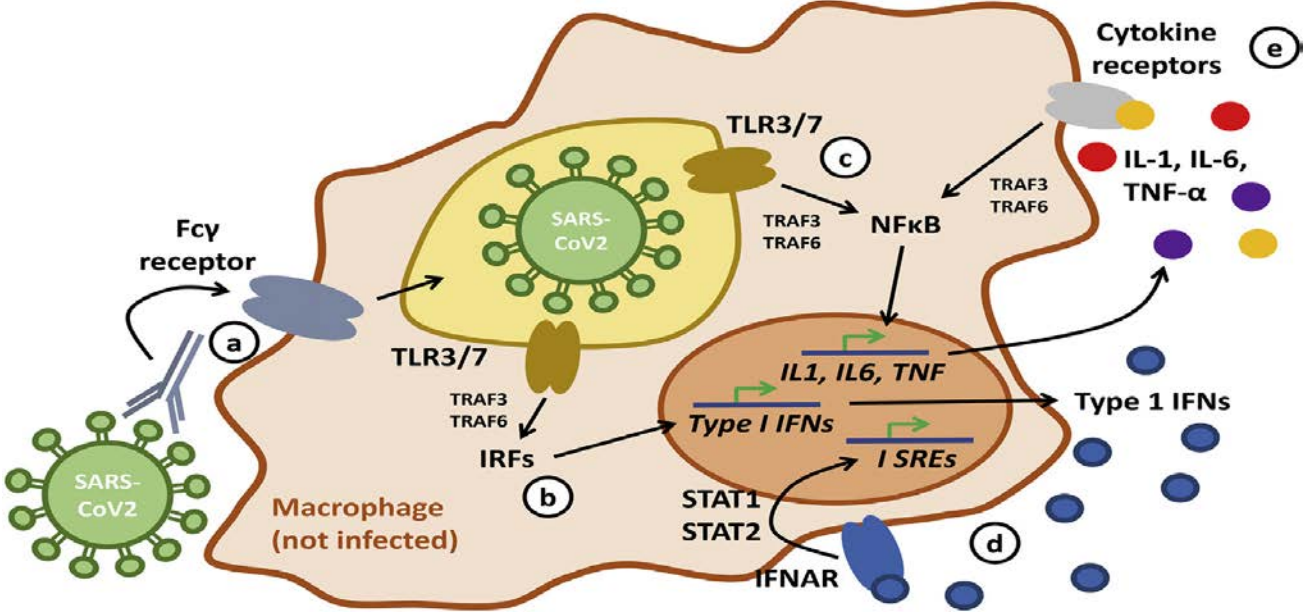
Clinical course



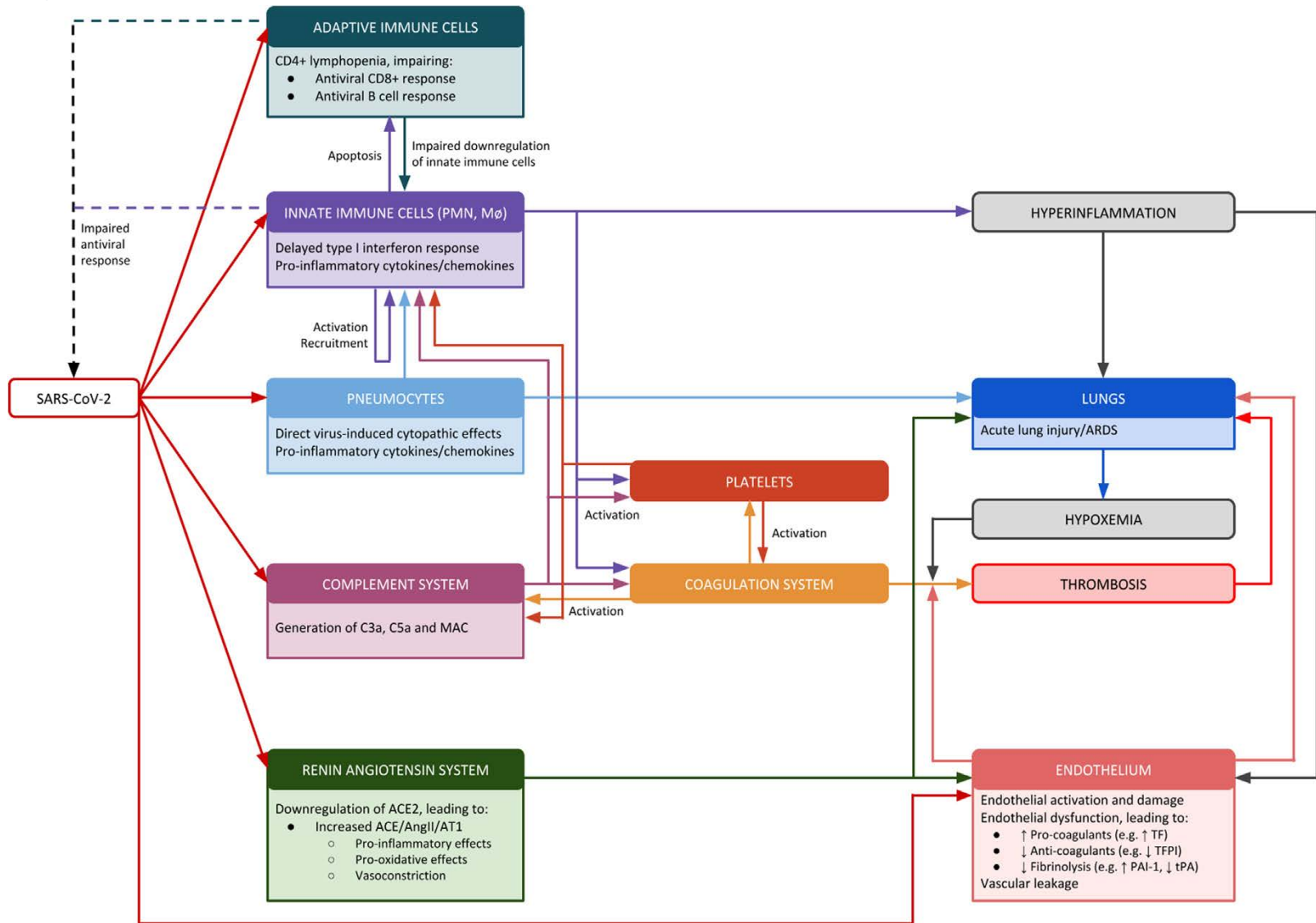
Mechanisms of cardiovascular manifestations



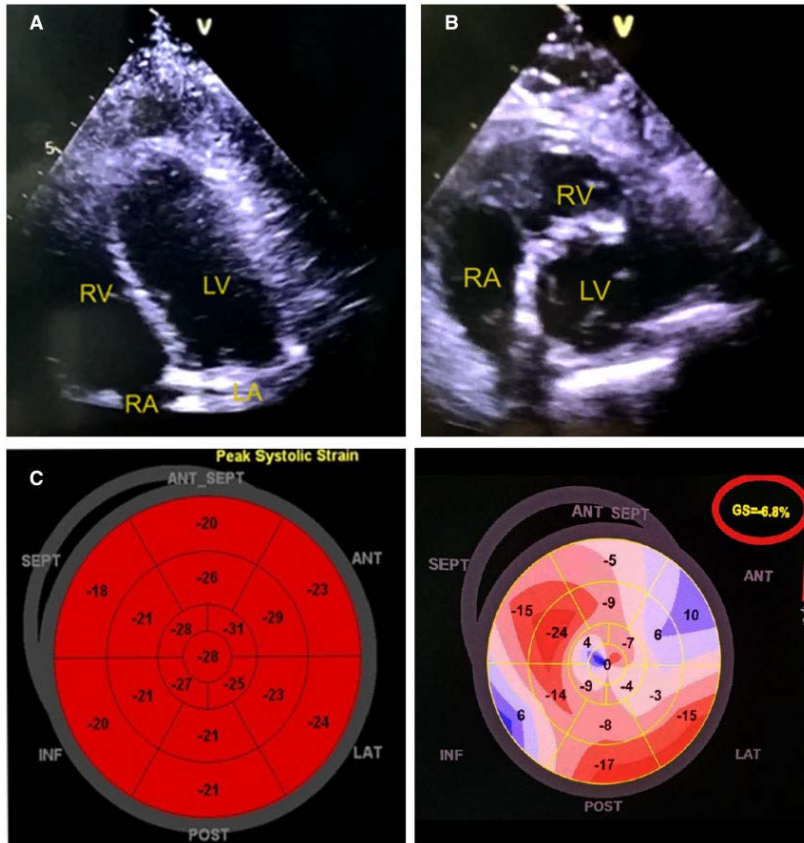
Cytokine storm



Cytokine storm⁷

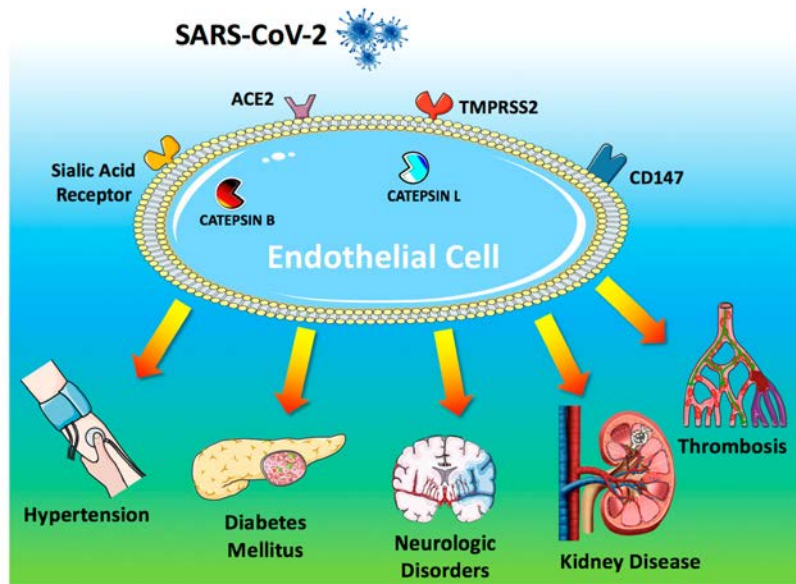


Myocarditis⁵



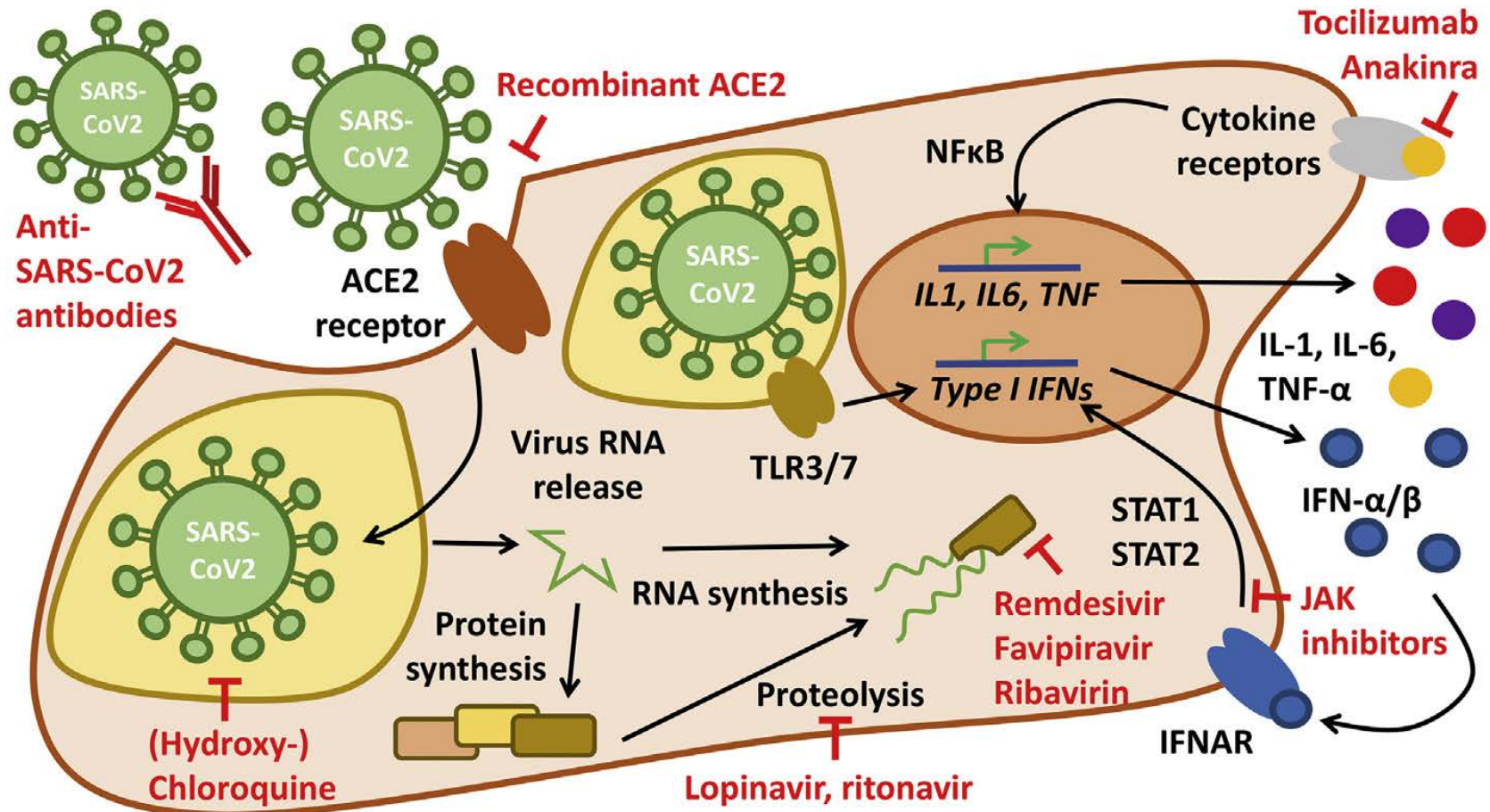
- Detailed history and physical examination.
- 12-lead ECG
- Serum high-sensitivity troponin, NT-proBNP
- Echocardiography
- Cardiac MRI
- Cardiac autoantibody titres

Endothelium injury⁸



- Kawasaki disease reported in young COVID-19 patients
- Hypertension treatment with ACE inhibitors or ARB⁹
- Acute kidney injury¹⁰
- Acute pulmonary embolism, DIC¹¹
- D-dimer > 1 $\mu\text{g/l}$ \rightarrow 18x risk

Therapeutic targets^{5,6}



Discussion

References

- [1] Wu Z, McGoogan JM. **Characteristics of and important lessons from the coronavirus disease 2019 (COVID-19) outbreak in China: summary of a report of 72314 cases from the Chinese center for disease Control and prevention.** J Am Med Assoc 2020.
- [2] The world health organization coronavirus disease 2019 (COVID-19) situation report 148 https://www.who.int/docs/default-source/coronaviruse/situation-reports/20200616-covid-19-sitrep-148-draft.pdf?sfvrsn=9b2015e9_2 . [Accessed 17 June 2020].
- [3] Zeng, J., Liu, Y., Yuan, J. et al. **First case of COVID-19 complicated with fulminant myocarditis: a case report and insights.** Infection (2020). <https://doi.org/10.1007/s15010-020-01424-5>
- [4] Magro C., Mulvey J. et al. **Complement associated microvascular injury and thrombosis in the pathogenesis of severe COVID-19 infection: a report of five cases.** Translational Research (2020) . <https://doi-org.ez.srv.meduniwien.ac.at/10.1016/j.trsl.2020.04.007>
- [5] Felsenstein S., Herbert J. et al. **COVID-19: Immunology and treatment options.** Clinical Immunology (2020). <https://doi.org/10.1016/j.clim.2020.108448>
- [6] Guzik T., Mohiddin S. et al. **COVID-19 and the cardiovascular system: implications for risk assessment, diagnosis, and treatment options.** Cardiovascular Research (2020). <https://doi-org.ez.srv.meduniwien.ac.at/10.1093/cvr/cvaa106>
- [7] Brandon M., Jens V. et al. **Hyperinflammation and derangement of renin-angiotensin-aldosterone system in COVID-19: A novel hypothesis for clinically suspected hypercoagulopathy and microvascular immunothrombosis** Clinica Chimica Acta (2020) <https://doi.org/10.1016/j.cca.2020.04.027>
- [8] Sardu C., Gambardella J. et al. **Hypertension, Thrombosis, Kidney Failure, and Diabetes: Is COVID-19 an Endothelial Disease? A Comprehensive Evaluation of Clinical and Basic Evidence.** Journal of Clinical Medicine (2020) <https://doi.org/10.3390/jcm9051417>
- [9] Zhang P, Zhu L. et al. **Association of Inpatient Use of Angiotensin Converting Enzyme Inhibitors and Angiotensin II Receptor Blockers With Mortality Among Patients With Hypertension Hospitalized With COVID-19.** Circ Res 2020 <https://doi.org/10.1161/CIRCRESAHA.120.317134>
- [10] Varga Z., Flammer A. et al. **Endothelial Cell Infection and Endotheliitis in COVID-19.** The Lancet (2020). [https://doi.org/10.1016/S0140-6736\(20\)30937-5](https://doi.org/10.1016/S0140-6736(20)30937-5)
- [11] Zhou F., Yu T. et al. **Clinical course and risk factors for mortality of adult inpatients with COVID-19 in Wuhan, China: a retrospective cohort study.** The Lancet (2020). [https://doi.org/10.1016/S0140-6736\(20\)30566-3](https://doi.org/10.1016/S0140-6736(20)30566-3)